



# Treating OCD and bone cysts

Diet plays a large role in minimizing developmental orthopedic diseases

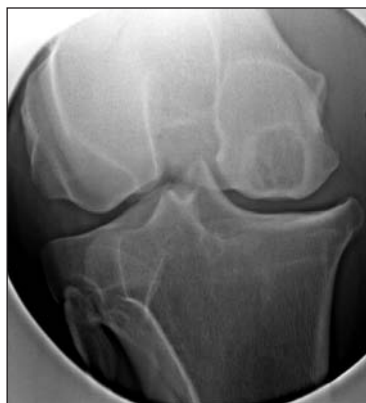HORSES OF all ages are prone to having hidden damage within their joints which can affect their soundness. OCD lesions (osteo-chondritis dissecans: bone cysts and osteochondral fragments) are mostly found in young horses such as yearlings. However, they also can first be discovered in older horses.

Sometimes OCD lesions are not noticeable, having no clinical effects even during initial race training, but create soundness issues later in a horse's career. They can cause increased joint swelling, or they can occur in otherwise normal-appearing joints.

There may be increased heat associated with affected joints, and the normal lubricating viscosity of the joint fluid may decrease. There may be soreness or unsoundness of varying degrees. Clinical problems are due to deterioration of the joint's otherwise normal cartilage that results in both the release of irritating pieces of cartilage and/or bone fragments (even microscopic) into

the lubricating joint fluid. There is also the resulting loss of normal bone/cartilage mechanical support, initiating an inflamed joint and early clinical arthritis.

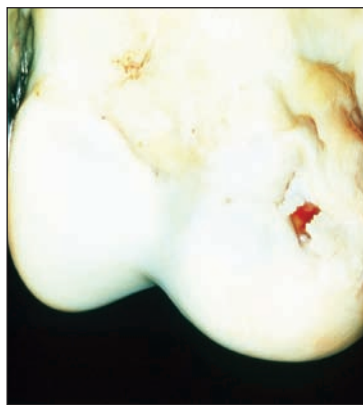
OCD cyst-like erosions of bone are single circular areas of decreased bone density, seen on radiographs, and found within the ends of bones, contained within joints. These weakened cystic areas of bone, which can create joint abnormalities, may lie just below the surface of what appears to be normal articular cartilage, or they may involve deterioration and/or loss of what should otherwise be normal joint cartilage. Technically, OCD also includes fractured composite pieces of bone and cartilaginous joint fragments that do not have to be associated with a bone cyst.



Radiograph stifle OCD on femur

OCD results from metabolic developmental bone diseases which start as a failure or interruption of normal bone maturation from fetal prebone cartilage. The disease is caused by disturbance of normal ma-

turing cartilage cells into abnormally retained and thickened cartilage. The thickened cartilage may die, develop cracks, produce fragments of combined bone and cartilage that detach into the joint, and/or develop into bone cysts. The causes are variable and consist of: a loss of blood supply due to local trauma; congenital deformities; excessive biomechanical force; and nutritional abnormalities, such as copper deficiency, that lead to connective tissue fragility.



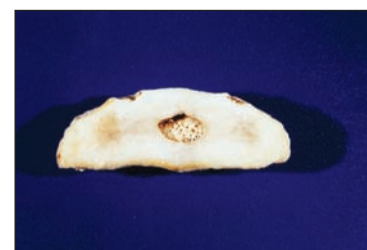
Stifle OCD cyst on femur

The joints most commonly affected by bone cysts include the hock, stifle, fetlock, elbow, and shoulder. Although cysts may occur simultaneously in identical joints of both right and left legs, it is uncommon for them to affect more than one type of joint in different locations at the same time.

While most bone cysts form before horses are six months of age, they are often diagnosed at a later age. Even though evident radiographically, some bone cysts either heal or become stable enough never

to be clinically relevant. Therefore, radiographically evident bone cysts should always be linked to clinical signs prior to therapy.

Surgery is a treatment option. However, with conservative care and/or controlled exercise, bone cysts can heal or they may subside in time. Surgery to remove bone-cartilage fragments and to eliminate bone cysts may be considered in horses without clinical signs if they are intended to be sold.



Navicular bone OCD cyst

Diagnosing joint disease due to OCD bone cysts or osteo-cartilaginous fragments can be challenging. Clinical signs such as excessive joint heat and swelling associated with unsoundness in select joints are helpful, but are often inconsistent in presentation. Blocking suspected joints with local anesthetic can be helpful. Radiographs are useful in determining cause, once an affected joint has been identified. Diagnostic nuclear scintigraphic imaging can be especially beneficial. However, such diagnostics may miss the identification of a quiet subclinical bone cyst.

Due to many types of OCD diseases in an assortment of varied locations, and due to unpredictable

results regarding a return to racing soundness, many varied treatments historically have been used. Administering local joint medications combined with rest or controlled exercise has been beneficial.

## Diet and OCD

A relationship may exist between too-rapid foal growth rates, too high a nutritional level, and too low a mineral content, specifically calcium, phosphorus, and copper.

Zinc, cadmium, and other minerals in competitively too high levels are considered toxic causes of OCD. The best method of diagnosing mineral deficiencies and toxicities is through ration evaluation. To a lesser degree, blood, hair, and hoof analysis also can be helpful.

Excessive energy intake due to high levels of carbohydrate (grain) feeding can cause too-rapid growth and increased body fat, increased blood glucose and insulin, and increased incidence of OCD.

Both sexes are equally affected and there is disagreement regarding the effects of exercise and the incidence of OCD. Some OCD lesions that have been identified in foals within one to three months of age have resolved by five to eight months of age. After eight months of age, however, most damage is permanent.

There are considerations for optimal feeding of mares and foals associated with six stages of pregnancy, birthing and foal maturity:

- 1) The first five to seven months of pregnancy require only minimal nutritional supplementation of mares.
- 2) After seven months of pregnancy, the nutrient requirements become significantly greater than the mare's maintenance requirements.

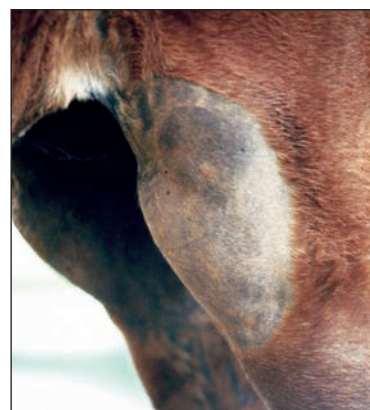- 3) A mare's nutrient requirements increase significantly after foaling because during the first three months of lactation, mares produce milk at a rate equal to about 3% of their body weight per day.

- 4) Giving mineral supplements to a suckling is unnecessary until it reaches 90 days of age.

- 5) From weaning to 12 months of age is the most critical stage of growth for avoiding developmental orthopedic disease, such as OCD.

- 6) Yearlings are less likely to develop OCD than are younger horses.

Commercially available nutritional supplements high in copper are available and have mixed therapeutic results. Qualified professional advice is recommended prior to choosing the best treatment for horses affected with OCD problems. Ⓞ



Visible stifle joint distention

**STRONGER BONE RESULTS IN PAIN-FREE JOINTS**



OCD™ Pellets provide the fundamental nutrients for **healthy bone development** and aids in resolving skeletal injuries and joint pain.

O  
OPTIMAL

C  
CARTILAGE

D  
DEVELOPMENT

PELLETS™

The only **BONE** supplement containing proven **JOINT** supplement **CORTA-FLX®**

[www.OCDPELLETS.com](http://www.OCDPELLETS.com)  
866-392-2363



Dr. Douglas R. Beebe  
Located in Lexington, KY

AAEP Booth  
#8107



Gregory Beroza, D.V.M., is founder of the Long Island Equine Medical Center in Huntington Station, New York. He is a practicing veterinarian of 31 years with board certification in both surgery and in practice. He is founder of EquiScan Nuclear Diagnostic Imaging and he publishes regularly under HorseDoc, "Talking Horses," at [www.horsedoc.com](http://www.horsedoc.com).